



KEMENTERIAN PENDIDIKAN, KEBUDAYAAN, RISET DAN TEKNOLOGI
UNIVERSITAS HASANUDDIN FAKULTAS KEDOKTERAN
KOMITE ETIK PENELITIAN UNIVERSITAS HASANUDDIN
RSPTN UNIVERSITAS HASANUDDIN
RSUP Dr. WAHIDIN SUDIROHUSODO MAKASSAR
Sekretariat : Lantai 2 Gedung Laboratorium Terpadu
JL.PERINTIS KEMERDEKAAN KAMPUS TAMALANREA KM.10 MAKASSAR 90245.



Contact Person: dr. Agussalim Bukhari.,MMed,PhD, SpGK TELP. 081241850858, 0411 5780103, Fax : 0411-581431

SURAT KETERANGAN

Nomor : 422 /H4.8.4.5.31/PP36 /2023

Komisi Etik Penelitian Kesehatan Fakultas Kedokteran Universitas Hasanuddin, menerangkan bahwa case report bukan penelitian sehingga tidak membutuhkan persetujuan etik. Sedangkan untuk publikasi case report cukup bahwa kerahasiaan data pasien di jaga dengan tidak mencantumkan nama maupun inisial sehingga tidak bisa diidentifikasi dan juga tindakan case report ini sudah mendapatkan informed consent dari pasien dan persetujuan untuk publikasi.

Jika ada hal yang ingin diklarifikasi silakan menghubungi sekretariat KEP (Komite Etik Penelitian) Universitas Hasanuddin.

Demikian surat keterangan ini dibuat untuk digunakan sebagaimana mestinya.

Makassar, 27 Juni 2023

Sekretaris



dr. Agussalim Bukhari, MMed,Ph.D,SpGK(K)
NIP 19700821 1999 03 1 001

Clinical Outcome Of Tolosa-Hunt Syndrome After Intravenous Steroid Therapy: A Case Report

Andi Kurnia Bintang,^{1*} Juliet Christy Gunawan Umbas,¹ Muhammad Iqbal Basri,² Jumraini Tammasse,¹

Abstract

Objective: Tolosa-Hunt syndrome (THS) is caused by an idiopathic inflammatory process in the cavernous sinus, superior orbital fissure, or orbit. THS is a rare disease. The main clinical symptoms are ophthalmoplegic pain, accompanied by ipsilateral headache, paresis of one or more ipsilateral III, IV, and/or VI cranial nerves, MRI or biopsy abnormalities, and cannot be categorized as other diseases. THS resolves adequately with corticosteroids within 24-72 hours of therapy.

Methods: Male 53 years old, was admitted for painful right ophthalmoplegia, constant onset, two weeks, ipsilateral headache, accompanied by diplopia and right eyelid ptosis. There was no history

of fever, trauma, or similar illness. Neurological examination showed exotropia due to paresis of the right III and IV cranial nerves. Analgesics can not relieve the pain. Laboratory findings, CT angiography, and brain MRI were normal.

Result: There was clinical improvement within 24 hours after initiation of methylprednisolone followed by tapering-off oral prednisone.

Conclusion: THS is a diagnosis of exclusion and must be distinguished from other causes of painful ophthalmoplegia. Careful follow-up is required to diagnose THS. The diagnosis should not depend on MRI alone but should be adjusted according to clinical findings and therapeutic response.

Keywords: Idiopathic Inflammation, Painful Ophthalmoplegia, Tolosa-Hunt Syndrome (THS).

Cite this Article: Bintang AK, Umbas JCG, Basri MI, Tammasse J. 2021. Clinical Outcome Of Tolosa-Hunt Syndrome After Intravenous Steroid Therapy: A Case Report. *Journal of Case Reports in Dental Medicine*. 3(3): 74-76. DOI: [10.20956/jcrdm.v3i3.165](https://doi.org/10.20956/jcrdm.v3i3.165)

¹Department of Neurology, Faculty of Medicine, Hasanuddin University, Makassar, Indonesia.

²Department of Anatomy, Faculty of Medicine, Hasanuddin University, Makassar, Indonesia.

Introduction

Tolosa-Hunt syndrome (THS) or ophthalmoplegic pain syndrome is an idiopathic disease that is rarely found. The etiology is still uncertain, but the granulomatous inflammatory process influences the pathophysiologic mechanism in the cavernous sinus, superior orbitalis fissure, or orbit.¹⁻³ Based on the 3rd edition of The International Classification of Headache Disorders, described as unilateral pain in the orbital or periorbital region accompanied by disturbances in one or more third, fourth, and/or sixth cranial nerves.³ Tolosa first proposed this syndrome in 1954, where patients had unilateral orbital pain symptoms and ophthalmoplegia.⁴ In 1961, Hunt et al. suggested that six THS patients experienced improvement after steroid therapy.⁵ The estimated incidence of the disease in the United States is 1:1,000,000 per year with an average onset of age 38-41 ± 14-16 years.⁴

Case Report

A man, 53 years old, came to our emergency department with pain at his right eyeball accompanied by an ipsilateral headache, experienced two weeks before being admitted. The patient felt a very uncomfortable sensation at the back of his right eye that continued constantly. One week after onset, the patient experienced double vision and followed by ptosis of the right eyelid. Patients have a history of hypertension that has been known for the past year

but was not treated regularly. There is no history of trauma and fever.

Physical examination at first admission, blood pressure was 170/110 mmHg and other vital signs within normal limits. Neurological examination found ptosis of right eyelid and exotropia of right eye. The right eye pupil was dilated (6mm), did not react to light and visual acuity decreased at the right eye. Funduscopic examination is within the normal. Other neurological examinations were unremarkable.

Laboratory tests which were complete blood, erythrocyte sedimentation rate, fasting blood sugar, kidney and liver function, electrolytes, coagulation, C-reactive protein (CRP), and thyroid function, found unremarkable. The electrocardiogram, chest x-ray, cerebral and carotid angiography, brain MRI and MRA were unremarkable.

Our patient was diagnosed with THS. He was given intravenous methylprednisolone (4 mg / Kg of BW) for three days. Within 24 hours after steroid therapy, orbital and head pain was reduced, ophthalmoplegia and ptosis of the right eye underwent a slight improvement. After the third day of steroid injection, the patient was discharged, then continued with oral prednisone 60 mg/day for seven days and tapering down 10 mg/week. One week later, the patient came to our outpatient clinic, and we found that painful ophthalmoplegia

*Correspondence to:
a.kurnia_b@yahoo.co.id

Received: 20 June 2021
Revised: 25 July 2021
Accepted: 15 August 2021
Available Online: 1 September 2021

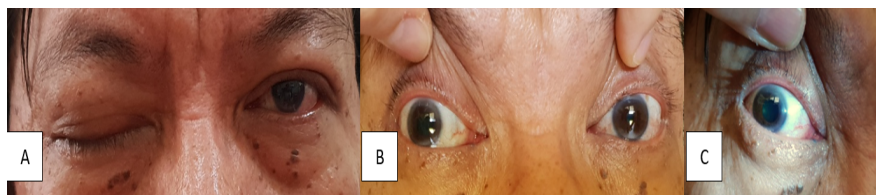


Figure 1 Ophthalmology examination showed
A. Right palpebral ptosis
B. Exotropia at the primary position of the right eye
C. Dilatation of the right eye pupil.

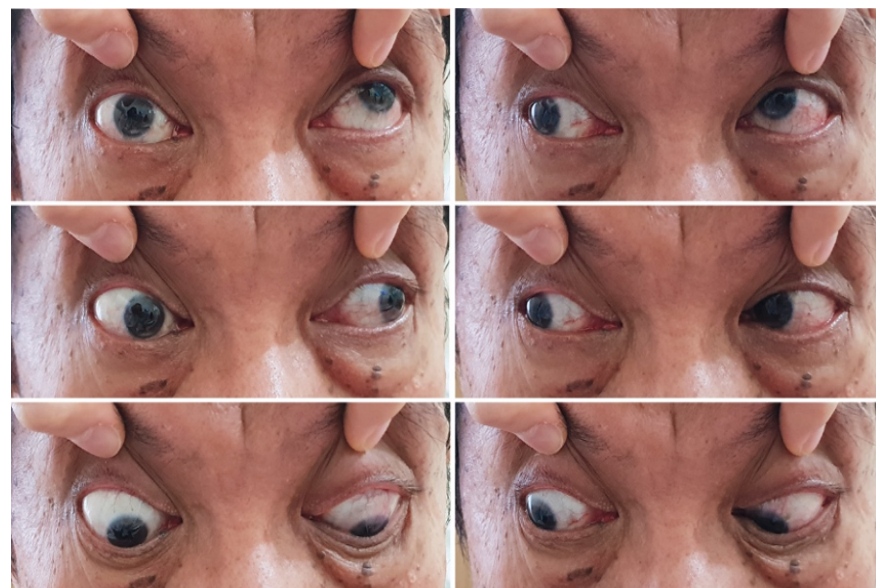

Figure 2 Paresis of Third and Fourth Cranial Nerves of the Right Eye.

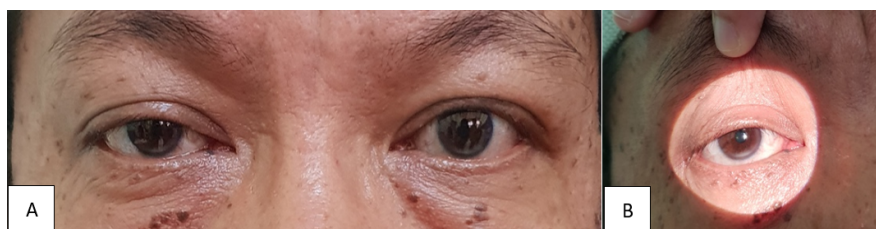

Figure 3 Improvement
A. Ptosis of the Right Palpebra
B. The Right Eye Pupils Reacted to the Light.

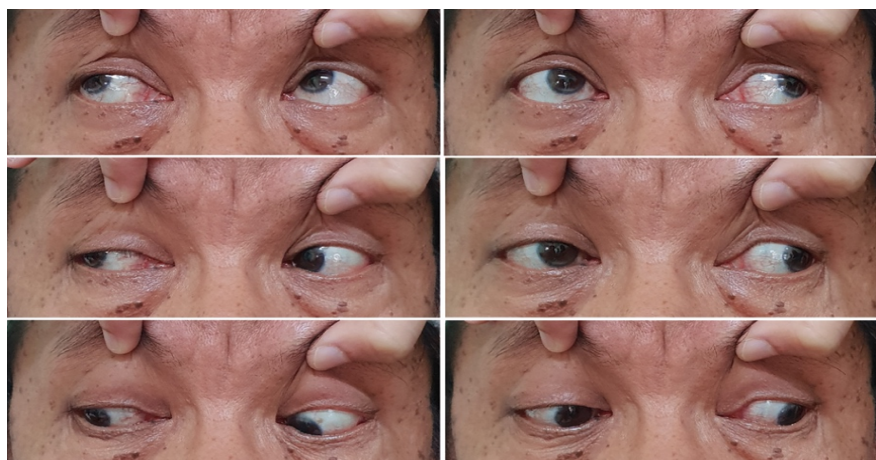


Figure 4 Improvement of third and fourth cranial nerves paresis.

and headache were absent; right eye ptosis had a significant improvement.

Discussion

THS has been described in the third edition of the International Headache Society (IHS) (ICHD-3 beta) as unilateral orbital regional pain associated with one or more III, IV, and or VI cranial nerves caused by granulomatous inflammation of the cavernous sinus, superior orbital fissures or orbit. There are several changes to the THS criterion in ICHD-3 beta [table 1](#) compared with the ICHD-II criteria.⁶

There are accompanying symptoms presented in several case reports: disturbance of the fifth, seventh, and eighth cranial nerves. The pupillary reflex is sometimes affected. THS is an exclusionary diagnosis,⁷ so the diagnosis must be carefully concluded to rule out other causes of ophthalmoplegic pain such as tumors, vasculitis, basal meningitis, sarcoidosis, or diabetes mellitus.³

There are several changes in ICHD-3 compared to ICHD-I and ICHD-II. One of them is the criteria that say that MRI has a vital role in diagnosing THS and getting rid of other diagnoses such as lymphoma, meningioma, and sarcoidosis. On the diagnostic criteria B.1 [Table 1](#), evidence of granulomatous inflammation in the cavernous sinus and surrounding areas is required through MRI or biopsy. If the results of the MRI are not found pathologically, then to prove the presence of granulomatous inflammation is through biopsy.

Based on the literature, THS lesions are generally located in the basal region of the cranium, which is difficult to access and close to other vital structures. Considering the risks and complications of our patients for their excellent response to steroids, we did not do a biopsy to confirm the diagnosis. THS with normal MRI has been reported in several case reports.⁷ Cakirer reported 3 (13%) patients with normal MRI from 23 patients.⁸ La Mantia et al. reviewed THS case reports from 1988-2002, of the 85 patients who met the THS diagnostic criteria, there were 41 (48.2%) patients having a normal MRI of a total of 85 patients.⁹ In 2013, Zhang et al. also reported 22 (47.8%) patients with normal MRI of a total of 46 patients.⁶

A review by Colnaghi et al. suggested the MRI scan should be set at a thickness of 3mm pieces.¹⁰ This cut arrangement is minimal and is usually made on a 3T MRI, while a 5mm thickness on MRI is 1.5T. However, there were no significant differences between MRI pieces 1.5 T/5 mm and 3T/3 mm, while lower spatial resolution had limitations in detecting granulomatous lesions.¹¹

Table 1. Diagnostic criteria of Tolosa Hunt Syndrome (ICHD-3 beta):

- A. Unilateral orbital or periorbital headache fulfilling criteria C
- B. Both of the following:
 1. Granulomatous inflammation of the cavernous sinus, superior orbital fissure or orbit, demonstrated by MRI or biopsy
 2. Paresis of one or more the ipsilateral IIIrd, IVth and/or VIth cranial nerves.
- C. Evidence of causation demonstrated by both of the following:
 1. Headache is ipsilateral to the granulomatous inflammation
 2. Headache has preceded paresis of the IIIrd, IVth and/or VIth nerves by ≤ 2 weeks, or developed with it
- D. Not better accounted for by another ICHD-3 diagnosis

Improvements in clinical symptoms of headache and ophthalmoplegia within 72 hours after administration of steroids have been excluded from the diagnostic criteria, but are still listed in additional information. It is due to general policy not to include therapeutic responses in diagnostic criteria.⁶ The ophthalmoplegic pain of our patients has drastically reduced in the first 24 hours after injection of intravenous methylprednisolone. There has also been minimal improvement in cranial nerve paresis. It correlates with the literature proposed by Zhang et al, who reported that pain complaints could be reduced by 60-70% within 72 hours after steroid therapy.⁶

Whereas cranial nerve neuropathy tends to be more slowly repaired, usually with steroid therapy within 2 to 8 weeks.⁸ The therapeutic response to corticosteroids is still very significant characteristics in THS cases, and resolution after steroid therapy is needed to confirm the final diagnosis of THS.⁶

Our patient was treated with 4mg/kg of BW of intravenous methylprednisolone for three days then continued with oral prednisone 60 mg / day for seven days and tapering of 10 mg/week. There is no standard dose of steroids for THS cases. Hung et. al., in their study, said that high-dose glucocorticoid therapy (prednisolone >0.5mg/kg of BW/day) had the same effect with low doses (prednisolone ≤ 0.5 mg/Kg of BW/day). In this case, low-dose glucocorticoids are recommended as therapy.¹¹

Conclusion

THS is an exclusion disease and must be distinguished from other causes of ophthalmoplegic pain. Careful monitoring is needed to rule out other

causes of ophthalmoplegic pain. Diagnosis cannot depend on MRI alone but can also be adjusted for clinical symptoms and response to therapy.

Acknowledgment

None.

Conflict of Interest

The authors affirm no conflict of interest in this paper.

References

1. Tolosa E. Periarteritic Lesions Of The Carotid Siphon With The Clinical Features Of A Carotid Intraclinoidal Aneurysm. *J Neurol Neurosurg Psychiatry.* 1954 Nov; 17(4):300-2.
2. Hunt WE. Tolosa-Hunt Syndrome: One Cause Of Painful Ophthalmoplegia. *J Neurosurg.* 1976 May; 44(5):544-9.
3. Olesen J. Headache Classification Committee of the International Headache Society (IHS) The International Classification of Headache Disorders, 3rd edition. *Cephalalgia.* 2018;38(1):1-211.
4. Hunt WE, Meagher JN, Lefever HE, Zeman W. Painful Ophthalmoplegia. Its relation to indolent inflammation of the cavernous sinus. *Neurology.* 1961 Jan;11:56-62.
5. Perez CA, Evangelista M. Evaluation and Management of Tolosa-Hunt Syndrome in Children: A Clinical Update. *Pediatr Neurol.* 2016;62:18-26.
6. Zhang X, Zhou Z, Steiner TJ, Zhang W, Liu R, Dong Z, et al. Validation of ICHD-3 beta diagnostic criteria for 13.7 Tolosa-Hunt syndrome: Analysis of 77 cases of painful ophthalmoplegia. *Cephalalgia.* 2014 Jul;34(8):624-32.
7. Abdelghany M, Orozco D, Fink W, Begley C. Probable Tolosa-Hunt syndrome with a normal MRI. *Cephalalgia.* 2015 Apr;35(5):449-52.
8. Cakirer S. MRI findings in Tolosa-Hunt syndrome before and after systemic corticosteroid therapy. *Eur J Radiol.* 2003 Feb;45(2):83-90.
9. La Mantia L, Curone M, Rapoport AM, Bussone G, International Headache Society. Tolosa-Hunt syndrome: critical literature review based on IHS 2004 criteria. *Cephalalgia.* 2006 Jul;26(7):772-81.
10. Colnaghi S, Versino M, Marchioni E, Pichiecchio A, Bastianello S, Cosi V, et al. ICHD-II diagnostic criteria for Tolosa-Hunt syndrome in idiopathic inflammatory syndromes of the orbit and/or the cavernous sinus.



This work is licensed under a Creative Commons Attribution

Clinical Outcome Of Tolosa-Hunt Syndrome After Intravenous Steroid Therapy: A Case Report

by Andi Kurnia Bintang

Submission date: 30-Dec-2021 06:17AM (UTC+0700)

Submission ID: 1736352827

File name: dr._Kurnia_Bintang.pdf (7.54M)

Word count: 2008

Character count: 10868

Clinical Outcome Of Tolosa-Hunt Syndrome After Intravenous Steroid Therapy: A Case Report

Andi Kurnia Bintang,¹ Juliet Christy Gunawan Umbas,¹ Muhammad Iqbal Basri,² Jumraini Tammasse,¹

Abstract

Objective: Tolosa-Hunt syndrome (THS) is caused by an idiopathic inflammatory process in the cavernous sinus, superior orbital fissure, or orbit. THS is a rare disease. The main clinical symptoms are ophthalmoplegic pain, accompanied by ipsilateral headache, paresis of one or more ipsilateral III, IV, and/or VI cranial nerves, MRI or biopsy abnormalities, and cannot be categorized as other diseases. THS resolves adequately with corticosteroids within 24-72 hours of therapy.

Methods: Male 53 years old, was admitted for painful right ophthalmoplegia, constant onset, two weeks, ipsilateral headache, accompanied by diplopia and right eyelid ptosis. There was no history

of fever, trauma, or similar illness. Neurological examination showed exotropia due to paresis of the right III and IV cranial nerves. Analgesics can not relieve the pain. Laboratory findings, CT angiography, and brain MRI were normal.

Result: There was clinical improvement within 24 hours after initiation of methylprednisolone followed by tapering-off oral prednisone.

Conclusion: THS is a diagnosis of exclusion and must be distinguished from other causes of painful ophthalmoplegia. Careful follow-up is required to diagnose THS. The diagnosis should not depend on MRI alone but should be adjusted according to clinical findings and therapeutic response.

Keywords: Idiopathic Inflammation, Painful Ophthalmoplegia, Tolosa-Hunt Syndrome (THS).

Cite this Article: Bintang AK, Umbas JCG, Basri MI, Tammasse J. 2021. Clinical Outcome Of Tolosa-Hunt Syndrome After Intravenous Steroid Therapy: A Case Report. *Journal of Case Reports in Dental Medicine*. 3(3): 74-76. DOI: [10.20956/jcrdm.v3i3.165](https://doi.org/10.20956/jcrdm.v3i3.165)

¹Department of Neurology, Faculty of Medicine, Hasanuddin University, Makassar, Indonesia.

²Department of Anatomy, Faculty of Medicine, Hasanuddin University, Makassar, Indonesia.

Introduction

Tolosa-Hunt syndrome (THS) or ophthalmoplegic pain syndrome is an idiopathic disease that is rarely found. The etiology is still uncertain, but the granulomatous inflammatory process influences the pathophysiologic mechanism in the cavernous sinus, superior orbital fissure, or orbit.^{1,3} Based on the 3rd edition of *The International Classification of Headache Disorders*, described as unilateral pain in the orbital or periorbital region accompanied by disturbances in one or more third, fourth, and/or sixth cranial nerves.³ Tolosa first proposed this syndrome in 1954, where patients had unilateral orbital pain symptoms and ophthalmoplegia.¹ In 1961, Hunt et al. suggested that six THS patients experienced improvement after steroid therapy.⁵ The estimated incidence of the disease in the United States is 1:1,000,000 per year with an average onset of age 38-41 ± 14-16 years.⁴

Case Report

A man, 53 years old, came to our emergency department with pain at his right eyeball accompanied by an ipsilateral headache, experienced two weeks before being admitted. The patient felt a very uncomfortable sensation at the back of his right eye that continued constantly. One week after onset, the patient experienced double vision and followed by ptosis of the right eyelid. Patients have a history of hypertension that has been known for the past year

but was not treated regularly. There is no history of trauma and fever.

Physical examination at first admission, blood pressure was 170/110 mmHg and other vital signs within normal limits. Neurological examination found ptosis of right eyelid and exotropia of right eye. The right eye pupil was dilated (6mm), did not react to light and visual acuity decreased at the right eye. Funduscopic examination is within the normal. Other neurological examinations were unremarkable.

Laboratory tests which were complete blood, erythrocyte sedimentation rate, fasting blood sugar, kidney and liver function, electrolytes, coagulation, C-reactive protein (CRP), and thyroid function, found unremarkable. The electrocardiogram, chest x-ray, cerebral and carotid angiography, brain MRI and MRA were unremarkable.

Our patient was diagnosed with THS. He was given intravenous methylprednisolone (4 mg / Kg of BW) for three days. Within 24 hours after steroid therapy, orbital and head pain was reduced, ophthalmoplegia and ptosis of the right eye underwent a slight improvement. After the third day of steroid injection, the patient was discharged, then continued with oral prednisone 60 mg/day for seven days and tapering down 10 mg/week. One week later, the patient came to our outpatient clinic, and we found that painful ophthalmoplegia

*Correspondence to:
a.kurnia_b@yahoo.co.id

Received: 20 June 2021
Revised: 25 July 2021
Accepted: 15 August 2021
Available Online: 1 September 2021

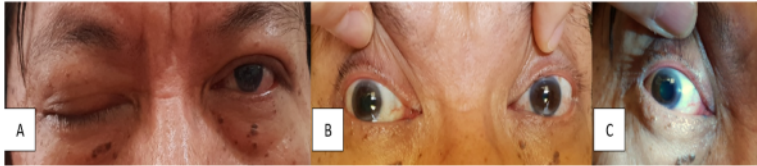


Figure 1 Ophthalmology examination showed
A. Right palpebral ptosis
B. Exotropia at the primary position of the right eye
C. Dilatation of the right eye pupil.

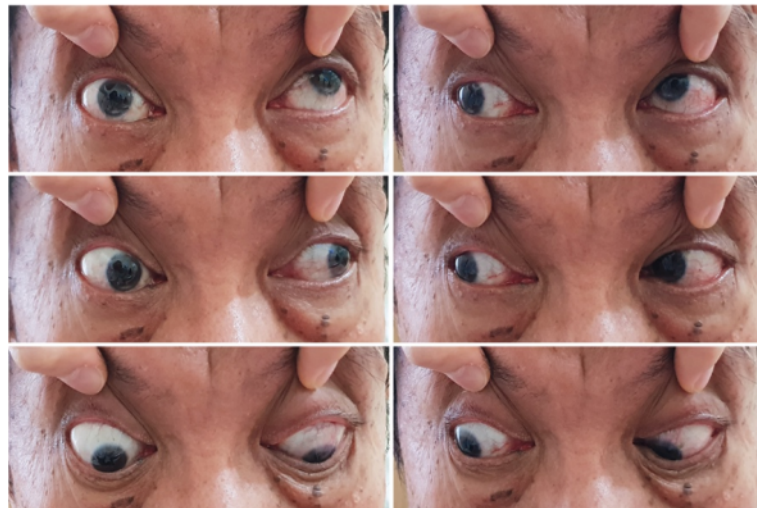

Figure 2 Paresis of Third and Fourth Cranial Nerves of the Right Eye.

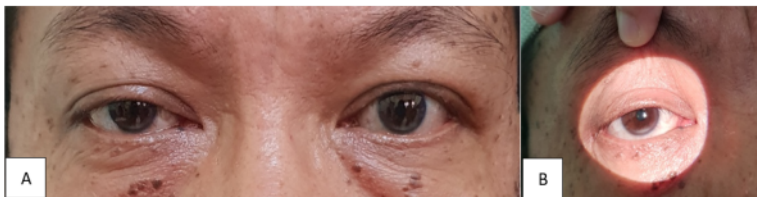

Figure 3 Improvement
A. Ptosis of the Right Palpebra
B. The Right Eye Pupils Reacted to the Light.

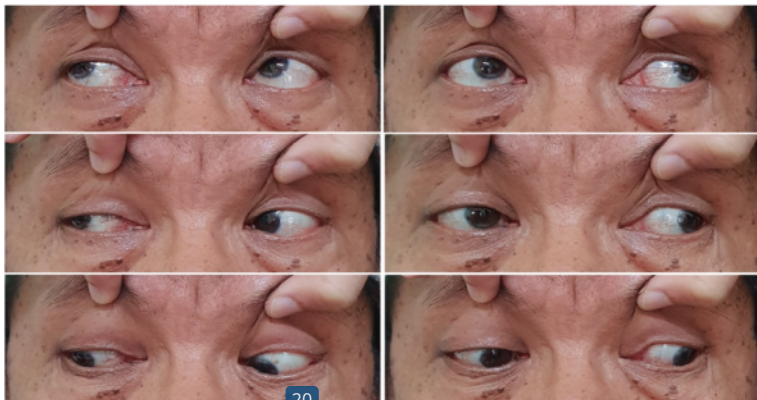

Figure 4 Improvement of third and fourth cranial nerves paresis.

and headache were absent; right eye ptosis had a significant improvement.

Discussion

THS has been described in the third edition of the International Headache Society (IHS) (ICHD-3 beta) as unilateral orbital regional pain associated with one or more III, IV, and or VI cranial nerves caused by granulomatous inflammation of the cavernous sinus, superior orbital fissures or orbit. There are several changes to the THS criterion in ICHD-3 beta table 1 compared with the ICHD-II criteria.

There are accompanying symptoms presented in several case reports: disturbance of the fifth, seventh, and eighth cranial nerves. The pupillary reflex is sometimes affected. THS is an exclusionary diagnosis, so the diagnosis must be carefully concluded to rule out other causes of ophthalmoplegic pain such as tumors, vasculitis, basal meningitis, sarcoidosis, or diabetes mellitus.

There are several changes in ICHD-3 compared to ICHD-I and ICHD-II. One of them is the criteria that say that MRI has a vital role in diagnosing THS and getting rid of other diagnoses such as lymphoma, meningioma, and sarcoidosis. On the diagnostic criteria B.1 Table 1, evidence of granulomatous inflammation in the cavernous sinus and surrounding areas is required through MRI or biopsy. If the results of the MRI are not found pathologically, then to prove the presence of granulomatous inflammation is through biopsy.

Based on the literature, THS lesions are generally located in the basal region of the cranium, which is difficult to access and close to other vital structures. Considering the risks and complications of our patients for their excellent response to steroids, we did not do a biopsy to confirm the diagnosis. THS with normal MRI has been reported in several case reports. Cakirer reported 3 (13%) patients with normal MRI from 23 patients. La Mantia et al. reviewed THS case reports from 1988-2002, of the 85 patients who met the THS diagnostic criteria, there were 41 (48.2%) patients having a normal MRI of a total of 85 patients. In 2013, Zhang et al. also reported 22 (47.8%) patients with normal MRI of a total of 46 patients.

A review by Colnaghi et al. suggested the MRI scan should be set at a thickness of 3mm pieces. This cut arrangement is minimal and is usually made on a 3T MRI, while a 5mm thickness on MRI is 1.5T. However, there are no significant differences between MRI pieces 1.5 T/5 mm and 3T/3 mm, while lower spatial resolution had limitations in detecting granulomatous lesions.

13
Table 1. Diagnostic criteria of Tolosa Hunt Syndrome

- 6** ICHD-3 beta):
- A. Unilateral orbital or periorbital headache fulfilling criteria C
 - B. Both of the following:
 1. Granulomatous inflammation of the cavernous sinus, superior orbital fissure or orbit, demonstrated by MRI or biopsy
 2. Paresis of one or more the ipsilateral IIIrd, IVth and/or VIth cranial nerves.
 - C. Evidence of causation demonstrated by both of the following
 1. Headache is ipsilateral to the granulomatous inflammation
 2. Headache has preceded paresis of the IIIrd, IVth and/or VIth nerves by ≤ 2 weeks, or developed with it
 - D. Not better accounted for by another ICHD-3 diagnosis

Improvements in clinical symptoms of headache and ophthalmoplegia within 72 hours after administration of steroids have been excluded from the diagnostic criteria, but are still listed in additional information. It is due to general policy not to include therapeutic responses in diagnostic criteria.⁶ The ophthalmoplegic pain of our patients has drastically reduced in the first 24 hours after injection of intravenous methylprednisolone. There has also been minimal improvement in cranial nerve paresis. It correlates with the literature proposed by Zhang et al, who reported that pain complaints could be reduced by 60-70% within 72 hours after steroid therapy.⁶

Whereas cranial nerve neuropathy tends to be more slowly repaired, usually with steroid therapy within 2 to 8 weeks.⁶ The therapeutic response to corticosteroids is still very significant characteristics in THS cases, and resolution after steroid therapy is needed to confirm the final diagnosis of THS.⁶

Our patient was treated with 4mg/kg of BW of intravenous methylprednisolone for three days then continued with oral prednisone 60 mg / day for seven days and tapering of 10 mg/week. There is no standard dose of steroids for THS cases. Hung et al., in their study, said that high-dose glucocorticoid therapy (prednisolone >0.5 mg/kg of BW/day) had the same effect with low doses (prednisolone ≤ 0.5 mg/Kg of BW/day). In this case, low-dose glucocorticoids are recommended as therapy.¹¹

Conclusion

THS is an exclusion disease and must be distinguished from other causes of ophthalmoplegic pain. Careful monitoring is needed to rule out other

causes of ophthalmoplegic pain. Diagnosis cannot depend on MRI alone but can also be adjusted for clinical symptoms and response to therapy.

Acknowledgment

None.

Conflict of Interest

The authors affirm no conflict of interest in this paper.

References

1. Tolosa E. Periarteritic Lesions Of The Carotid Siphon With The Clinical Features Of A Carotid Intraclinoidal Aneurysm. *J Neurol Neurosurg Psychiatry*. 1954 Nov; 17(4):300-2.
2. Hunt WE. Tolosa-Hunt Syndrome: One Cause Of Painful Ophthalmoplegia. *J Neurosurg*. 1976 May; 44(5):544-9.
3. Olesen J. Headache Classification Committee of the International Headache Society (IHS) The International Classification of Headache Disorders, 3rd edition. *Cephalalgia*. 2018;38(1):1-211.
4. Hunt WE, Meagher JN, Lefever HE, Zeman W. Painful Ophthalmoplegia. Its relation to indolent inflammation of the cavernous sinus. *Neurology*. 1961 Jan; 11:56-62.
5. Perez CA, Evangelista M. Evaluation and Management of Tolosa-Hunt Syndrome in Children: A Clinical Update. *Pediatr Neurol*. 2016;62:18-26.
6. Zhang X, Zhou Z, Steiner TJ, Zhang W, Liu R, Dong Z, et al. Validation of ICHD-3 beta diagnostic criteria for 13.7 Tolosa-Hunt syndrome: Analysis of 77 cases of painful ophthalmoplegia. *Cephalalgia*. 2014 Jul;34(8):624-32.
7. Abdelghany M, Orozco D, Fink W, Begley C. Probable Tolosa-Hunt syndrome with a normal MRI. *Cephalalgia*. 2015 Apr;35(5):449-52.
8. Cakire S. MRI findings in Tolosa-Hunt syndrome before and after systemic corticosteroid therapy. *Eur J Radiol*. 2003 Feb;45(2):83-90.
9. La Mantia L, Curone M, Rapoport AM, Bussone G, International Headache Society. Tolosa-Hunt syndrome: critical literature review based on IHS 2004 criteria. *Cephalalgia*. 2006 Jul;26(7):772-81.
10. Colnaghi S, Versino M, Marchioni E, Pichiecchio A, Bastianello S, Cosi V, et al. ICHD-II diagnostic criteria for Tolosa-Hunt syndrome in idiopathic inflammatory syndromes of the orbit and/or the cavernous sinus.



This work is licensed under a Creative Commons Attribution

Clinical Outcome Of Tolosa-Hunt Syndrome After Intravenous Steroid Therapy: A Case Report

ORIGINALITY REPORT

21 %
SIMILARITY INDEX

16 %
INTERNET SOURCES

21 %
PUBLICATIONS

9 %
STUDENT PAPERS

PRIMARY SOURCES

1 www.thieme-connect.com **3** %
Internet Source

2 journals.sagepub.com **2** %
Internet Source

3 Chih-Hsien Hung, Kuo-Hsuan Chang, Yi-Ming Wu, Yao-Liang Chen et al. "A comparison of benign and inflammatory manifestations of Tolosa-Hunt syndrome", Cephalalgia, 2013 **2** %
Publication

4 moam.info **2** %
Internet Source

5 Jumraini Tammasse, Natalia Tening Lawing, Abdul Muis, Muhammad Iqbal Basri, Andi Kurnia Bintang. "The effect of repetitive peripheral magnetic stimulation on insomnia improving and pain in patients with chronic low back pain", Medicina Clínica Práctica, 2021 **1** %
Publication

6 www.ncbi.nlm.nih.gov **1** %
Internet Source

7	<p>Hung, Chih-Hsien, Kuo-Hsuan Chang, Yao-Liang Chen, Yi-Ming Wu, Chiou-Lian Lai, Hong-Shiu Chang, Rong-Kuo Lyu, Yih-Ru Wu, Chiung-Mei Chen, Chin-Chang Huang, Chun-Che Chu, Chun-Hung Chen, and Long-Sun Ro. "Clinical and Radiological Findings Suggesting Disorders Other Than Tolosa-Hunt Syndrome Among Ophthalmoplegic Patients: A Retrospective Analysis", Headache The Journal of Head and Face Pain, 2015.</p> <p>Publication</p>	1 %
8	<p>researchpub.org</p> <p>Internet Source</p>	1 %
9	<p>www.jkna.org</p> <p>Internet Source</p>	1 %
10	<p>Marcellin Bugeme, Ousmane Cissé, Olivier Mukuku, Amadou Gallo Diop. "Tolosa-Hunt Syndrome: A Painful Ophthalmoplegia", Case Reports in Neurological Medicine, 2020</p> <p>Publication</p>	1 %
11	<p>www.acepnw.com</p> <p>Internet Source</p>	1 %
12	<p>Charles Taylon. "Giant cell granuloma involving the pituitary gland : Case report", Journal of Neurosurgery, 04/1980</p> <p>Publication</p>	1 %

13	L La Mantia, M Curone, AM Rapoport, G Bussone. "Tolosa–Hunt Syndrome: Critical Literature Review Based on IHS 2004 Criteria", <i>Cephalalgia</i> , 2016 Publication	1 %
14	headachejournal.pericles-prod.literatumonline.com Internet Source	1 %
15	C Zanus, C Furlan, P Costa, D Cosentini, M Carrozzi. "The Tolosa-Hunt Syndrome in Children: A Case Report", <i>Cephalalgia</i> , 2009 Publication	1 %
16	Cakirer, S.. "MRI findings in Tolosa-Hunt syndrome before and after systemic corticosteroid therapy", <i>European Journal of Radiology</i> , 200302 Publication	1 %
17	scindeks-clanci.ceon.rs Internet Source	1 %
18	Carlos A. Pérez, Monaliza Evangelista. "Evaluation and Management of Tolosa–Hunt Syndrome in Children: A Clinical Update", <i>Pediatric Neurology</i> , 2016 Publication	1 %
19	Abdullah Ashraf Rafique Ali, Justin Yeak, Norlina Ramli. "Tolosa-Hunt Syndrome with underlying latent tuberculosis: a diagnostic	<1 %

dilemma", International Journal of
Ophthalmology, 2021

Publication

20

Rui Hao, Yanjin He, Hong Zhang, Wei Zhang,
Xiaorong Li, Yifeng Ke. "The evaluation of
ICHD-3 beta diagnostic criteria for Tolosa-
Hunt syndrome: a study of 22 cases of
Tolosa-Hunt syndrome", Neurological
Sciences, 2015

Publication

<1 %

Exclude quotes On

Exclude matches < 5 words

Exclude bibliography On